

A Severe Asphyxiated Newborn: A Case Report

Atiye Fedakâr MD. Pediatrician*

The Departments of Pediatrics, Afiyet Hospital, Ümraniye, İstanbul, Turkey.

Zakir Sakcı MD, Radiology

The Departments of Radiology, Sağlık Bilimleri Üniversitesi Ümraniye Eğitim
Araştırma Hastanesi, Ümraniye, İstanbul, Turkey

*Corresponding Author: atyfedakar@hotmail.com

A Severe Asphyxiated Newborn: A Case Report

Abstract

Perinatal asphyxia is still a major cause of mortality and morbidity despite significant improvements in neonatal intensive care. The incidence of perinatal asphyxia is 6/1000 in term infants, and it is the third leading cause of death after prematurity and sepsis. Perinatal asphyxia is an important cause of permanent damage to the central nervous system which may result in cerebral palsy and developmental disability later on. It can also affect renal, gastrointestinal, and hepatic systems and may cause severe non-reversible sequelae. Therefore, management of asphyxic newborns, appropriate resuscitation, and planning of follow-up and treatment by an experienced team are helpful to reduce mortality and morbidity. Herein, we report a severe asphyxiated newborn in the light of literature review.

Keywords: Perinatal asphyxia, newborn.

Introduction

Perinatal asphyxia is a clinical process in which hypoxia and ischemia coexist. It can be defined as the clinical depression table associated with hypoxia, hypercapnia and acidosis in the newborn and/or fetus depending on the impairment of the functions of the biological unit consisting of mother, fetus and placenta and the impairment of postpartum pulmonary gas exchange. According to the clinical findings, it is the clinical presentation in the newborn which develops due to low Apgar score, acidosis in the cord blood and hypoxic ischemic encephalopathy (1,2). Although the reported values for the incidence of perinatal asphyxia are variable due to differences in diagnostic criteria, the incidence of perinatal asphyxia is reported to be 6/1000 in the literature (3,4). Also, asphyxia (23%) is the third most common cause of newborn deaths after premature birth (28%) and sepsis (26%)(5).

Herein, we report a severe asphyxiated newborn in the light of literature review.

Case Report

A 42-year-old mother, in her third pregnancy, gave birth to a male term baby weighing 2615 g with cesarean section due to fetal distress. His height was 46cm and the head circumference was 33cm. After birth, his overall condition was very poor, his heart was not beating, and he was not breathing. There were ecchymosis around the umbilicus and the chest area. He had respiratory depression and the Apgar score was 0 at the first min and 2 at the fifth min. Cornea was dull and pupillary light reflex was weak. The blood pressure was 70/30 mmHg. There was no other abnormal finding. Following resuscitation and intubation, he was referred to the intensive care unit with the diagnosis of severe asphyxia. There were two costal fractures on the left side on posteroanterior chest X-ray. The echogenicity of the bilateral kidney parenchyma found to be increased in abdominal ultrasound (USG) and cranial sulci were present on cranial USG (Figure-1

A chest X-ray image of the patient). His personal and familial history were unremarkable. In the first arterial blood gas analysis; pH was 7.36 mm/Hg, PCO₂ was 113 mm/Hg, PO₂ was 103 mm/Hg, HCO₃ was 9.5 mmol/L, BE was -25 mmol/L. In blood count analysis, leukocyte count was 69.140mm³; platelet count was 65.000 mm³, Htc59%, and Hgb 18g/dL. In biochemical analysis of blood; Na was 129 mmol/L, blood glucose was 37mg/dL, and CRP was 3.52mg/dL(reference <0.5). Total urine analysis revealed protein positivity. The metabolic screening tests were normal. The mortality score was 32.6% according to the Score for Neonatal Acute Physiology and Perinatal Extension II(SNAPPE-II). The newborn was internalized with the diagnosis of asphyxia and was connected to the ventilator in the SIMV mode. For hypoglycemia, 2cc of 10% dextrose was administered as bolus and 10% maintenance fluid was initiated. When glucose failed to recover, the fluid was uptitrated to 12.5%. NaHCO₃ was also administered for severe metabolic acidosis. Prophylactic phenobarbital was applied due to asphyxia. Cultures were obtained due to poor overall status of the patient and low platelet and high leukocyte counts were detected. Meropenem + vancomycin + intravenous immunoglobulin were administered. Posteroanterior chest X-ray also revealed an intensive infiltration. Echocardiography(ECHO) showed pulmonary hypertension+patent foramen ovale. Sildenafil was planned for pulmonary hypertension;however, it was unable to be administered, as the gastric content was dirty and contained bile. Ranitidine and metronidazole were added to the treatment. Hypoglycemia, hyponatremia, and metabolic acidosis were stabilized after 24 hours. In the biochemical blood analysis on Day 3, 25OHvitamin D₃ was <3ng/mL, Ca was 7.6 mg/dL, total protein was 3.9 mg/dL, albumin was 2 mg/dL, AST was 1999 U/L, ALT was 614 U/L, LDH was 3422 U/L, creatine kinase was 7070 U/L (reference 24-170),PT time was 45 sec (reference 11-15 s), PT activity was 16% (reference 70-100), INR was 4.97, urea was 77 mg/dL, and creatinine was 2.73 mg/dL. Diffuse edema was also detected in physical examination.

Fresh frozen plasma was administered at 10 cc/kg, human albumin was administered for two days. One-fourth of vitamin D vial was applied intramuscularly. As the levels of the hepatic enzymes were elevated, phenobarbital was discontinued. Vancomycin was switched to teicoplanin due to high urea level. In the ECHO performed on Day 6 postnatally, pulmonary hypertension was recovered. The levels of AST was 110 U/L, ALT was 93 U/L, LDH was 1506 U/L. Since platelet count was detected as 31.000mm^3 in the blood count, platelet suspension was administered at 10cc/kg for two days. On postnatal Day 7, repeated cranial USG showed a milimetric calcification in left ventricle and abdominal USG revealed ascites and Grade 1 ectasia. Urea was 109 mg/dL and creatinine was 2.4 mg/dL. Acute renal failure secondary to severe asphyxia was considered. The urine output was good. The patient was consulted with pediatric nephrology. Since the gastric content was clear on the postnatal Day 8, enteral feeding was started minimally. On the postnatal Day 14, upon severe increase in the distention of the abdomen, the erect abdominal plain film was obtained and bowel perforation was detected. The patient was operated urgently by the pediatric surgeons. On the postoperative Day 2, his overall status deteriorated again and he was taken to operation twice. Meanwhile, gastric perforation developed (Figures 2-3 The erect abdominal plain graphy of the patient, the appearance of abdominal distention). The stomach was repaired by the pediatric surgeon (Figure 4. Postoperative overall status of the patient). The patient, who started to receive enteral feeding on the postoperative Day 4, was discharged with cure on the postnatal Day 34. The hepatic enzymes and creatine kinase were normal on Day 7, the blood count returned to normal on Day 14 and renal functions returned to normal on Day 21. He was followed under mechanical ventilation for 20 days.

Discussion

Perinatal asphyxia is one of the major causes of mortality and morbidity in newborns, even in developed countries, despite recent developments in neonatal care,

diagnosis and treatment. According to the estimates of the World Health Organization, 3% of all infants in developing countries are suffering from asphyxia, 23% of them die due to newborn asphyxia, and in the same number of infants, serious sequelae remain (6).

It is reported that 20% of perinatal asphyxia develops in the antepartum period, 35% in the intrapartum period, 35% in the intrapartum-antepartum period and 10% in the postnatal period (7). Although 90% of perinatal asphyxia occurs due to intrauterine and intrapartum events, asphyxia time may not be determined in many cases (6,7). In our case we attributed the perinatal asphyxia to the advanced maternal age, emergent cesarean birth due to fetal distress, and the antepartum causes. It has been reported in the literature that cerebral palsy due to perinatal asphyxia is encountered more in males (10). Similarly, the Turkish Society of Neonatology reported that three fourth of the babies who were diagnosed with asphyxia were male (10), as in our case.

The Apgar score is often used to determine the clinical condition of the newborn at birth. The prolonged duration of the low Apgar score is associated with mortality and the increased likelihood of neurological morbidity in the surviving newborns (8). In term infants, if the Apgar score is between 0 and 3 in the 1st minute and it does not improve at 20 minutes, then the mortality increases from 5.6 to 59% (11,12). The Apgar score of our patient was 0 at the first min and 2 at the fifth min.

In perinatal asphyxia, blood flow is rearranged so as to provide more oxygen support to vital organs such as the brain and heart. In this case, there may be damage to the organs such as the kidney, liver and intestine which are already affected by hypoxia. In the literature, the additional organ involvement is reported as central nervous system (72%), pulmonary (71-86%), cardiac (43 to 78%), renal (46 to 72%), liver (80 to 85%), hematological (32 to 54%), and gastrointestinal tract (29%) following the asphyxia (13,14,15).

In a study conducted by Star et al. (16) with 205 cases, the kidney was identified as the mostly affected organ with 40.5%. In the study of Shah et al. (14), they reported that

the hepatic involvement was 85%, pulmonary involvement was 86% and renal involvement was 70%. In our case, the central nervous system being in the first place, pulmonary, cardiac, renal and gastrointestinal systems were affected. The most severely affected system was the gastrointestinal system in which postnatal both intestinal and gastric perforation developed secondary to mesenteric ischemia on Day 14 of asphyxia. The intestinal and gastric perforations were repaired by the pediatric surgeon.

The effect of perinatal asphyxia on bone marrow can be seen as thrombocytopenia. Thrombocytopenia may continue up to 12 hours to three days, particularly after brain damage. It may cause intracranial hemorrhage (8). In our case, thrombocyte count was 65.000 mm³ on the first day and thrombocyte count was 31.000 mm³ on the third day. Therefore, platelet suspension was administered at a dose of 10cc/kg for two days. Since the PT time was long, fresh frozen plasma was administered for two days to prevent possible bleeding complications.

As a result of renal system involvement secondary to asphyxia, the levels of creatinine and urea may increase, oliguria-anuria may occur, fluid retention and hyponatremia due to inappropriate release of anti-diuretic hormone may develop. It is reported in the literature that as a result of liver dysfunction, the liver enzymes such as ALT, AST, LDH, particularly in the first 3-4 days may elevate, hypoglycemia may occur and there may be prolongation of coagulation studies (8,17).

Adequate ventilation, heat, perfusion, supply of glucose, calcium and acid-base balance are the gold standard in treatment. One of the major causes of neurological damage in asphyxiated neonates is the timing of postnatal ventilation and perfusion. For this reason, it is very important to monitor the oxygen and carbon dioxide levels and keep them within the normal limits (11).

In our case, right after the resuscitation and intubation, cardiac and respiratory support was commenced. Hypoglycemia, hyponatremia and metabolic acidosis improved after 24 hours. The infection was taken under control with the appropriate

antibiotic treatment. Hepatic enzymes and creatine kinase levels were normal on Day 7 and renal functions returned to normal on Day 20.

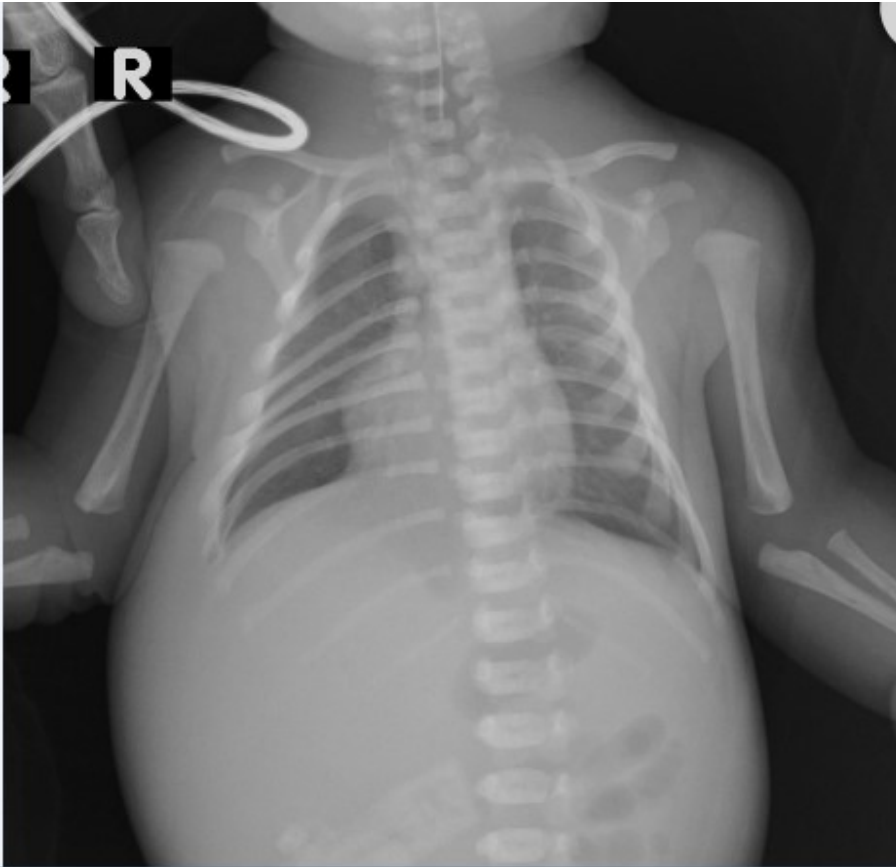
In conclusion, perinatal asphyxia may develop in intrauterine period, during birth or in the postnatal period. Recognition of risky cases, their referral to perinatal centers, adequate antenatal care in pregnancy, foresightful approach of the experienced health personnel to the newborn with asphyxia, appropriate and adequate resuscitation are crucial in terms of reducing mortality and morbidity.

References

1. Can G. Neonatal asfiksi. *Pediatric I. Neyzi O, Ertuğrul T. 2. baskı. Nobel tıp Kitapevi, İstanbul 1993; 235-241*
2. Nelson BK, Levintan A. How much of neonatal encephalopathy is due to birth asphyxia? *AJDC 1991; 145:1325-31.*
3. Can G. Perinatal asfiksi. İçinde: Yurdakök M, Erdem G, editör. *Türk Neonatoloji Derneği, Neonatoloji 2.baskı. Ankara: Alp Ofset; 2004. s. 719-28.*
4. de Haan M, Wyatt JS, Roth S, Vargha-Khadem F, Gadian D, Mishkin M. Brain and cognitive-behavioural development after asphyxia at term birth. *Dev Sci. 2006;9:350-8.*
5. Lawn JE, Cousens S, Zupan J and for the Lancet Survival Steering team. 4 million neonatal deaths: when? where? why? *Lancet. 2005;365:891-900*
6. Tekin N. Perinatal asfiksini önlenmesi ve yönetimi *Perinatoloji Dergisi 2011;19(Suppl 1): S36-S39*
7. Schifrin BS. The CTG and the timing and mechanism of fetal neurological injuries. *Best Pract Res Clin Obstet Gynaecol 2004;18:437-56*
8. Antonucci R., Porcella A., Pilloni M. D. Perinatal asphyxia in the term newborn *journal of Pediatric and Neonatal Individualized Medicine . vol. 3 . n. 2 . 2014*
9. Johnston MV, Hagberg H. Sex and the pathogenesis of cerebral palsy. *Dev Med Child Neurol 2007; 49: 74-78.*
10. Türk Neonatoloji Derneği Hipoksik İskemik Ensefalopati Çalışma Grubu. Türkiye’de yenidoğan yoğun bakım ünitelerinde izlenen hipoksik iskemik ensefalopatili olgular, risk faktörleri, insidans ve kısa dönem prognozları. *Çocuk Sağlığı ve Hastalıkları Dergisi 2008;51:123-9*
11. Volpe JJ. *Neurology of Newborn. 3th ed. WB Saunders Company, 1995; 211-360*
12. Fanaroff AA, Martin RJ. *Neonatal-Perinatal Medicine. 5th ed. Mosby Year Book, St. Louis 1992; 702-723.*

13. Martin-Ancel A, Garcia-Alix A, Gaya F, Cabanas F, Burgueros M, Quero J. Multiple organ involvement in perinatal asphyxia. *J Pediatr* 1995;127:786-93.
14. Shah P, Riphagen S, Beyene J, Perlman M. Multiorgan dysfunction in infants with post-asphyxial hypoxic ischaemic encephalopathy. *Arch Dis Child Fetal Neonatal Ed* 2004;89:152-5.
15. Acunaş B, Çeltik C, Garipardıç M, Karasalihođlu S. Perinatal asfiksili yenidođanların etyoloji, klinik ve prognoz aısından deęerlendirilmesi. *T Klin J Pediatr* 1999;8:21-6.
16. Satar M, Narlı N, Kırımı E, Atıcı A, Türkmen M, Yapıcıođlu H. Evaluation of 205 neonates with hypoxic ischemic encephalopathy. *Türkiye Klinikleri J Pediatr* 2001;10:36-41.
17. Belet N, Küçüködük Ş, Sancak R. Perinatal asfiksili term yenidođanlarda karaciđer fonksiyonlarının deęerlendirilmesi. *T Klin J Pediatr* 1998;7:129-32.

Figure-1 A chest X-ray image of the patient



(Figures 2-3 The erect abdominal plain graphy of the patient, the appearance of abdominal distention

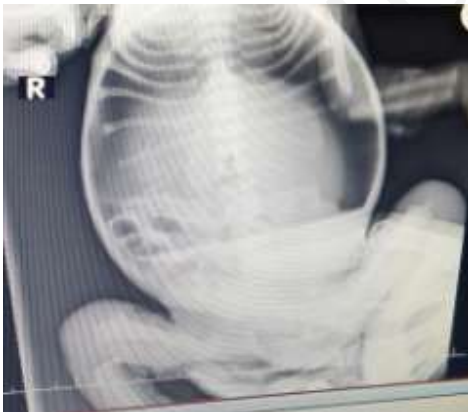
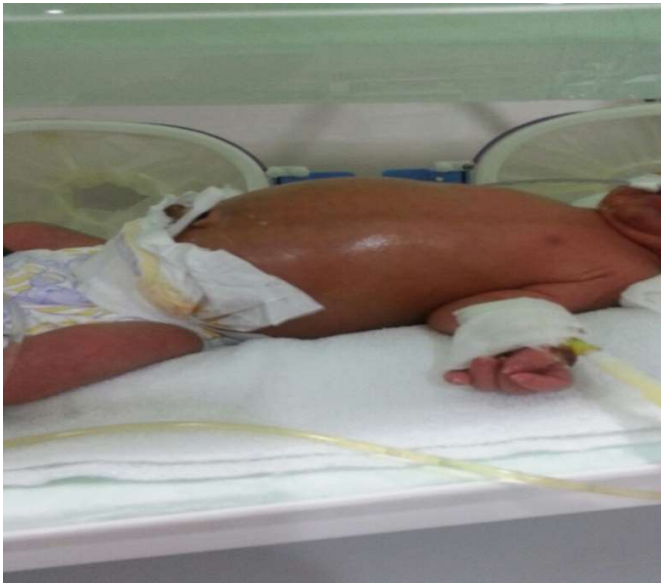
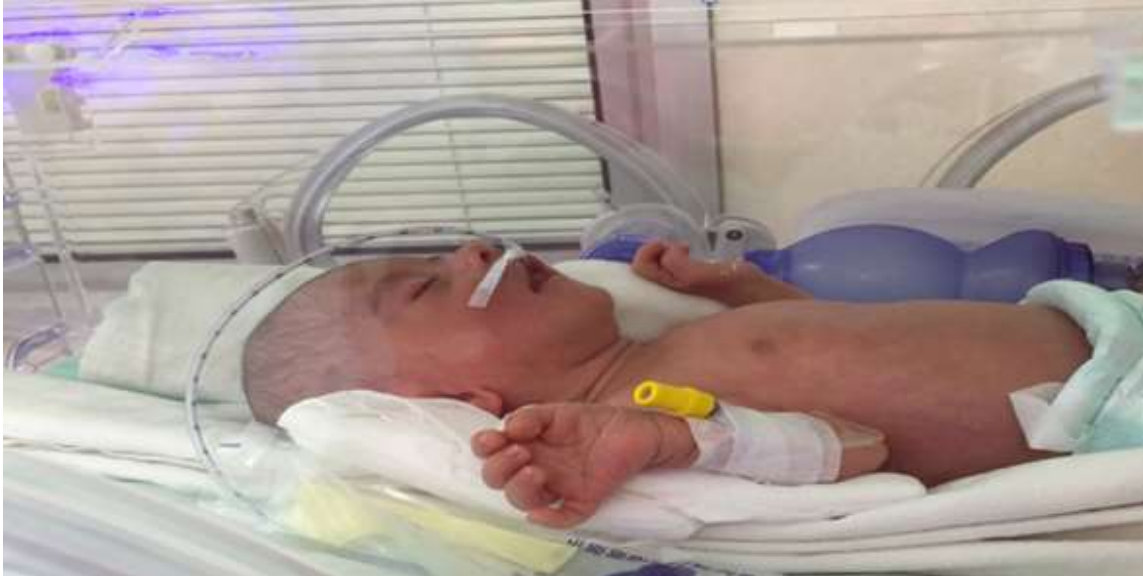Figure 4. Postoperative overall status of the patient



COMMUNICATIONS IN APPLIED SCIENCES